

---

# Phrenic Nerve Reconstruction for Diaphragmatic Paralysis and Ventilator Dependency

# 10

Matthew Kaufman, Thomas Bauer, Mary Massery,  
and John Cece

---

## Introduction

The integration of advanced surgical methods aimed at restoring form and function in the human body into the paradigm of rehabilitation medicine has, until recently, lagged in the area of neuromuscular respiratory disorders. For several decades, reconstructive surgeons have been reporting on various procedures to improve function to a paralyzed arm or leg, including reconstructive nerve surgery, muscle or tendon transfers, and joint fusions. A natural synergy has occurred over time, where clinicians caring for patients with paralysis and spinal cord injury have an understanding of the surgical options and communicate with their surgical colleagues regarding proper patient selection for operative intervention.

However, neuromuscular dysfunction within the respiratory system has generally been the sole responsibility of the clinician, other than referral for tracheostomy or, more recently, diaphragm pacemakers. This lack of communication limits successful reversal of the disorder when noninvasive methods fail. It is the fault of neither the clinician nor surgeon in developing, recognizing, or promoting similar surgical options for patients with neuromuscular respiratory disorders. Rather, it has been a lack of focus or basic training of any surgical specialty to pursue functional restoration of the neuromuscular pathways in the respiratory system and a misconception that most central and/or peripheral nerve lesions within this system cannot be overcome.

An anatomical basis for pursuing surgical techniques to reverse respiratory paralysis exists just as it does for any other peripheral motor system in the human body. For direct insults to the primary peripheral respiratory nerve, i.e., the phrenic nerve, microsurgical methods of nerve reconstruction can be applied to restore or supplement axonal continuity and overcome diaphragmatic paralysis.

Successful surgical intervention to restore neuromuscular recovery following injury can occur provided the following basic principles apply. First, there must be inherent maintenance of the ability for peripheral nerve regeneration within the individual's nervous system. The capacity for nerve regeneration is maintained in peripheral nerves, even in patients with spinal

---

M. Kaufman, MD, FACS (✉) • J. Cece, BAS  
The Plastic Surgery Center, Institute for Advanced  
Reconstruction, 535 Sycamore Ave, Shrewsbury,  
NJ 07702, USA  
e-mail: [matthewrkmd@gmail.com](mailto:matthewrkmd@gmail.com);  
[mkaufmanmd@theplasticsurgerycenternj.com](mailto:mkaufmanmd@theplasticsurgerycenternj.com);  
[john.cece@gmail.com](mailto:john.cece@gmail.com)

T. Bauer, MD  
Jersey Shore University Medical Center,  
1945 NJ 33, Neptune, NJ 07753, USA  
e-mail: [TBauer@meridianhealth.com](mailto:TBauer@meridianhealth.com)

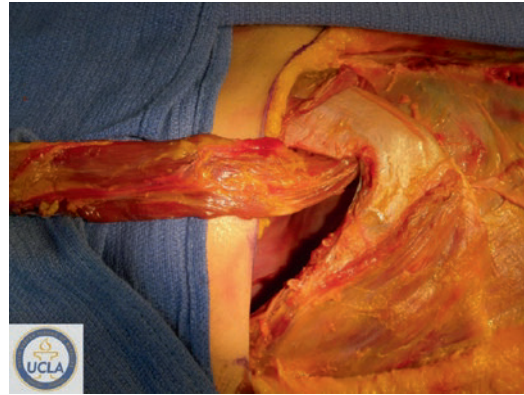M. Massery, PT, DPT, DSc (✉)  
Massery Physical Therapy, 3820 Timbers Edge Lane,  
Glenview, IL 60025, USA  
e-mail: [mmassery@aol.com](mailto:mmassery@aol.com)

cord injury. Second, surgical methods must be meticulous and precise. Surgical precision provides the scaffold upon which the regenerative process can occur. Finally, there must be adequate rehabilitation of the muscle once reinnervation has been confirmed. Restoration of normal or near-normal nerve conduction to a muscle, especially a rather large muscle like the diaphragm, will only result in muscle recovery and regrowth if intensive rehabilitation is instituted.

Insults to the central nervous system, including spinal cord injury, stroke, or tumor, may result in ventilator dependency when the neural pathways are interrupted between the brainstem respiratory centers and the peripheral circuitry. Diaphragm pacemakers, a topic discussed in detail in the following chapter 11, may offer a tremendous therapeutic benefit to reduce or eliminate the need for mechanical ventilation and minimize the associated morbidity and mortality associated with long-term ventilatory support. Unfortunately, there are a subset of patients for whom pacemakers will provide little or no benefit.

A requirement for successful application of a diaphragm pacemaker is phrenic nerve integrity. When individuals have insults to their central nervous system in locations that also results in loss of the anterior horn cells, there is resultant peripheral Wallerian degeneration in the phrenic nerves. It has been estimated that 18% of all spinal cord injured patients have generalized peripheral axonal neuropathy, with tetraplegics having an even higher incidence [1]. These patients are often told to expect a life-long dependency on the ventilator. Recently, we have been able to demonstrate the restoration of phrenic nerve integrity using reconstructive nerve surgery, permitting successful use of a diaphragm pacemaker, a report that supplements an earlier, primary description of these methods [2, 3]. For these unfortunate patients, there may be an option to overcome the debilitating and life-shortening impact of chronic ventilator dependency.

In our quest to have a range of reconstructive surgical options to remedy the neuromuscular dysfunction regardless of severity, we are developing methods for diaphragm muscle replacement. Just as facial or upper extremity muscles can be



**Fig. 10.1** Exposure of diaphragm through transthoracic approach and mobilization of pedicled rectus abdominis muscle flap in a cadaver (Courtesy and with gratitude to donors of UCLA Donated Body Program)

“replaced” by transferring vascularized, innervated muscle from somewhere else in the body, and expect it to function in a similar manner to that which it is replacing, the same may be true for the diaphragm. When these capabilities are realized through ongoing clinical evaluation, the surgical options would be comprehensive in nature in terms of replacing most major components of the neuromuscular pathways within the respiratory system. Specifically, the absence of a derived impulse due to the CNS (central nervous system) disorder could be overcome by the transmitted impulse from the diaphragm pacemaker, a nerve transfer to restore axonal circuitry to the degenerated phrenic nerve, and a muscle that has not undergone denervation atrophy (in a high cervical tetraplegic), such as the rectus abdominis, may be transferred to replace or enhance what may be an irreversibly atrophic diaphragm (Fig. 10.1).

---

## Neuromuscular Anatomy and Physiology of the Respiratory System

### Central Pathways

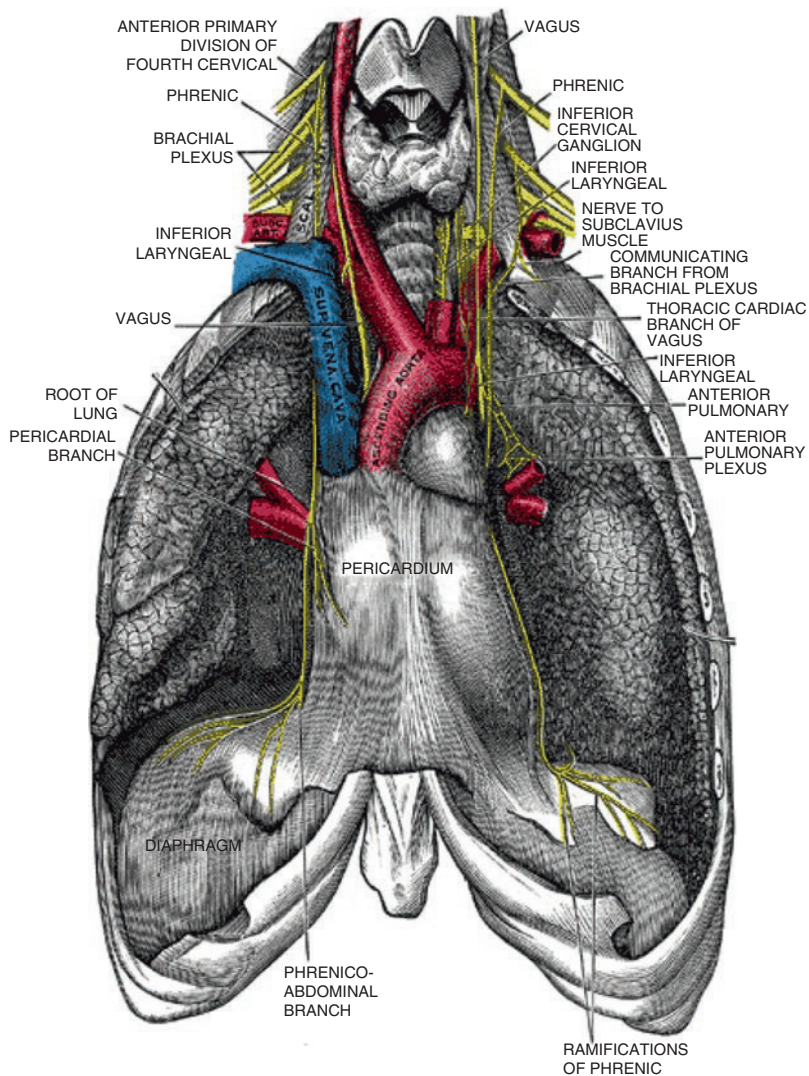
The anatomy and physiology of the respiratory system is somewhat unique. There is a baseline level of involuntary activity necessary to sustain breathing during sleep as well as a conscious

“override” that may be invoked. Brainstem nuclei transmit impulses through the anterior horn cells to initiate an inspiratory effort. Alternatively, respiratory centers in the cerebral cortex may stimulate a respiratory event through a conscious effort. There are established connections between both sides of the brainstem, including a described “cross phrenic phenomenon,” whereby a cord hemisection disrupting ipsilateral respiratory activity will be restored

through a rerouting of impulses from the contralateral, uninjured side [4–6].

## The Muscles of Respiration

After descending to the upper cervical region (C3-5), the conduction proceeds extradural through the cervical roots and phrenic nerves, downward toward each hemidiaphragm (Fig. 10.2). The



**Fig. 10.2** Neuromuscular pathway of the respiratory system, including the phrenic nerves arising from the third through fifth cervical roots; the descent of the phrenic nerves through the cervical region, mediastinum, and

chest cavities; and the intramuscular branching pattern of the phrenic nerve within the diaphragm to innervate all muscular segments

diaphragm is the primary inspiratory muscle, working in conjunction with several accessory respiratory muscles to expand the thoracic cavity in a vertical dimension, while intercostal muscles are primarily responsible for horizontal expansion of the ribcage. The entire process is a coordinated ensemble of contraction in the trunk musculature, including the trapezius, sternocleidomastoid, pectoralis major/minor, small strap muscles of the neck (hyoid musculature), intercostals, and abdominal muscles. The lung expands passively as a result of the facilitated increased thoracic domain, and an exchange of inspired gases occurs. The diaphragm maintains a critical role in this process through its action of increasing thoracic volume and opposing abdominal forces acting against it. The expiratory phase of breathing involves a different subset of muscles aimed at reversing the dimensions of the thoracic cavity back to its resting state.

### The Phrenic Nerve

The phrenic nerve is a peripheral nerve arising from C3-5 and contains primarily motor fibers, although there are a small group of sensory fibers innervating primarily the pericardium. The course of the nerve is deep in the neck, subjacent to the prevertebral fascia, and just above the anterior scalene muscle (Fig. 10.3). A majority of



**Fig. 10.3** Phrenic nerve (looped) coursing longitudinally along anterior scalene muscle (overlying prevertebral fascia has been cleared)

humans also have a smaller branch, called the accessory phrenic nerve, which runs a parallel but often variable course in the neck, typically joining the more dominant phrenic nerve proper at the base of the neck or in the mediastinum [7]. After entering the mediastinum, the phrenic nerve increases in caliber and travels between the lung and midline structures. In the region of the heart, the phrenic nerves on both sides are located close to or within the pericardial fat and descend within these tissues to reach their terminal insertions in the medial portions of each diaphragm. The nerves branch rather extensively within each hemidiaphragm in order to innervate all portions of these broad and wide muscles.

### The Diaphragm

The primary respiratory muscle is skeletal in nature and is divided into two hemidiaphragms by its midline central tendon. The lateral attachments to each chest wall and its position in the center of the trunk account for its importance in body posture and stability. An excellent reference for the diaphragm's role as a postural stabilizer [8]. The structural makeup of the diaphragm consists of approximately 50% slow-twitch (type I) and fast-twitch (type II) muscle fibers according to postmortem human research [9, 10]. The resting thickness of the diaphragm muscle when measured at its so-called zone of apposition is estimated to be roughly 1.5 mm, expanding by 2 mm with functional activation [11].

### Diaphragmatic Paralysis

#### Incidence and Etiology

The true incidence of diaphragmatic paralysis is currently unknown, in part because of the variety of etiologies. The most common peripheral etiologies are iatrogenic or traumatic events impacting the neck, mediastinum, or chest (Table 10.1). Cardiac surgery procedures such as coronary artery bypass or valve replacement have been associated with phrenic nerve injury or abnormal diaphragm findings in anywhere from 1 to 80% of cases [12–14].

**Table 10.1** Suspected etiology of diaphragmatic paralysis in published series

Suspected etiology	No. (%)
Nerve block (interscalene/epidural)	18 (27)
Neck/spine trauma	16 (24)
Cardiac operation	11 (16)
Neck operation (thyroid, lymphadenectomy)	5 (7)
Chiropractic	5 (7)
Thymectomy	3 (4)
Radiofrequency ablation (cardiac)	3 (4)
Thoracic outlet operation	3 (4)
Carotid-subclavian bypass	2 (3)
Pulmonary lobectomy	2 (3)
Total	68 (100)

Reprinted with permission, Kaufman et al., *Annals of Thoracic Surgery*

Interscalene nerve blocks performed for shoulder surgery previously resulted in a 100% incidence of temporary diaphragmatic paralysis as a result of anesthetic effect on the phrenic nerve. However, altered dosing regimens and use of ultrasound guidance have reduced the risk [15, 16]. Permanent diaphragmatic paralysis after interscalene block has been reported, though the incidence has not been determined [17, 18]. Chiropractic neck manipulation also has been associated with phrenic nerve injury in the neck, likely a result of either a traction-type nerve injury from the sudden jolting or perhaps a post-inflammatory effect on the nerve, especially if recurrent treatments prevent complete internal healing to occur [19, 20]. Other surgical procedures in the neck that have been reported to have an association with diaphragmatic paralysis include: carotid-subclavian bypass, thoracic outlet surgery, and cervical lymphadenopathy [21].

Mediastinal procedures such as thymectomy, especially for malignancy, have an association with phrenic nerve injury with a reported rate of 1–2% [22, 23]. Aortic or mitral valve repairs/replacements may lead to phrenic nerve injury in the upper thoracic cavity. It is not yet known whether recently developed, minimally invasive methods of valve surgery will alter incidences of nerve injury. Phrenic nerve injury resulting from cardiac bypass surgery is most often due to either hypothermic damage from the use of heart cooling

or direct injury during isolation and transfer of the internal mammary artery pedicle. Procedures performed to alleviate atrial fibrillation, such as the MAZE procedure and cardiac ablation, have both been reported to result in diaphragm paralysis. Patients with this etiology of phrenic nerve dysfunction have been evaluated, and their conditions are successfully reversed by the senior author (M.R.K) using techniques discussed below [3, 24].

Carcinoma of the lung requiring partial or complete resection may require intentional sacrifice of the phrenic nerve or, alternatively, result in diaphragmatic paralysis as an unintended consequence [25]. Patients undergoing lung transplantation may also suffer the effects of phrenic nerve injury due to the extensive restructuring of the thoracic cavity [26]. Trauma to the neck and chest may also lead to isolated phrenic nerve injuries or in combination with other neural structures, such as the brachial plexus or cranial nerves. A severe traction injury, when the shoulder is jolted forcefully in an opposite direction from the neck, puts substantial tension on the nerves coursing through the lower lateral cervical region [27]. Furthermore, there is often a resulting inflammatory process creating edema within the soft tissues of the neck. If this process does not resolve rather rapidly, the result is post-inflammatory fibrosis and adhesions.

Similar to other compression neuropathies in the upper and lower extremities, the phrenic nerve may easily be entrapped within the confines of its intra-fascial pathway, leading to conduction disturbances. A chronic, severe compression of any peripheral nerve may lead to segmental anoxia and axonal loss, a process that cannot be reversed spontaneously despite our inherent ability for nerve regeneration [28].

There may be certain patients who may be more susceptible to iatrogenic and traumatic phrenic nerve injury. The *double-crush* phenomenon, originally described by Upton and McKomas in 1973, describes the susceptibility of a second site of nerve injury along a neural pathway when one already exists [29]. For example, patients with cervical spine radiculopathy are more susceptible to carpal tunnel syndrome [30]. Similarly, patients with unilateral or bilateral phrenic nerve injuries

resulting from trauma or surgery commonly present with degenerative cervical disease impacting the third through fifth cervical roots. We have also evaluated and treated numerous patients for diaphragmatic paralysis who have known, or subclinical cervical disease, but do not provide a clear traumatic or iatrogenic etiology. While the C-spine MRI often demonstrates foraminal narrowing or mild spinal stenosis in these patients, the only presenting clinical symptom is chronic dyspnea with exertion from a paralyzed diaphragm.

Idiopathic paralysis and viral neuritis (i.e., Parsonage-Turner syndrome) are other etiologies for diaphragmatic paralysis reported in the literature [31, 32]. Parsonage-Turner syndrome was originally described in 1948 as a condition that only affected the brachial plexus but is now used interchangeably, in addition to neuralgic amyotrophy, to describe isolated or combined insults to the brachial plexus and phrenic nerve(s) as a result of an inflammatory neuropathy. Although viral neuritis has very specific presenting sign and symptoms (e.g., fever, malaise, arm weakness, nausea/vomiting) that may be correctly diagnosed when exhibited in close temporal relation to the onset of dyspnea, idiopathic paralysis is truly a diagnosis of exclusion.

Central nervous system disorders may also cause diaphragmatic paralysis, often with bilateral muscle dysfunction, resulting in the need for oxygen supplementation or dependency on mechanical ventilation. Rates of ventilator dependence in high cervical spinal cord injury can reach as high as 71 % [33]. It is estimated that 20 % of these injuries will also result in Wallerian degeneration within the phrenic nerves as a result of the loss of anterior horn cells.

Amyotrophic lateral sclerosis (ALS) and other bulbospinal neuropathies lead to demyelination and axonal loss within the phrenic nerves. Diaphragmatic paralysis in ALS almost universally results in complete ventilator dependency in later stages of the disease and, ultimately, is one of the leading causes of mortality [34]. Other CNS conditions that are associated with diaphragmatic paralysis include: central hypoventilation syndrome, brainstem tumor, stroke, and cervical cord compression [35, 36].

## Signs and Symptoms

Unilateral diaphragmatic paralysis will rarely result in a need for mechanical ventilation. However, in this clinical scenario, there is often a co-diagnosis of sleep-disordered breathing for which nocturnal positive pressure oxygen may be necessary [37]. Individuals with this disorder typically report dyspnea with exertion, orthopnea, and easy fatigability [38]. Quality of life assessments reveal disturbances on measures of physical functioning and indicate that traditional perceptions suggesting *one can live unaffected by a paralyzed diaphragm* have underestimated the significance of the problem [3]. Other presenting symptoms of unilateral paralysis include: gastroesophageal reflux for left-sided diaphragmatic paralysis, chest wall discomfort, abdominal bloating, chronic cough, breathlessness, depression, and postural asymmetries/pain.

On examination, the most obvious finding is diminished breath sounds at the base on the involved side when auscultating the lung fields. Occasionally, there will be a Tinel's sign in the supraclavicular region of the neck, supporting the diagnosis of a phrenic neuropathy in the cervical region. Unless the diagnosis is due to a major insult to the cervical roots and/or brachial plexus, examination of the upper extremities will be unremarkable. Alternatively, traumatic injury to the brachial plexus has a reported association with diaphragmatic paralysis due to phrenic nerve injury in 10–20 % of cases [39].

## Evaluation

Diaphragmatic paralysis is most reliably diagnosed on a *sniff test* – chest fluoroscopy performed with a deep nasal inspiratory effort – and is revealed by either absence of movement or paradoxical (upward) movement, indicating a flail, atonic diaphragm muscle. Paretic muscle dysfunction, or partial paralysis, may also be diagnosed by observing reduced descent of the muscle upon inspiration, when compared to the contralateral, normally functioning side. For most patients, performing the diagnostic study in supine and upright positions can reveal differences that may

assist in qualifying the severity of the dysfunction. The sniff maneuver may also be performed while observing with ultrasonography, thus permitting more accurate measurements of diaphragm thickness.

Spirometry evaluation in patients with diaphragmatic paralysis will typically reveal a restrictive ventilatory deficit, though well-conditioned individuals with unilateral paralysis may often have the percent predicted values within a normal range for their age. Alternatively, there are other patients with diaphragmatic paralysis who develop secondary pulmonary disorders, such as asthma or sleep-disordered breathing, and demonstrate mixed restrictive-obstructive deficits on spirometry testing. When bilateral diaphragmatic dysfunction is present, for example, in patients with cervical stenosis, the results of spirometry testing will usually indicate much more severe restrictive ventilatory deficiencies.

Radiographic imaging using CT or MRI modalities is almost always appropriate to rule out organic pathology, such as degenerative cervical disease or tumor, and should be recommended based on the particulars of patient history. For example, individuals with a history of neck or back pain, especially with concomitant upper extremity weakness or paresthesias, require cervical MRI to look for cord compression. Alternatively, patients with diaphragmatic paralysis, whose history is significant for benign or malignant tumors of the thyroid, thymus, breast, or lung, require imaging to eliminate tumor pathology causing neural injury.

Electrodiagnostic evaluation is important for quantifying the extent of phrenic nerve injury and severity of muscle atrophy and is discussed more thoroughly in its own chapter. The phrenic nerve conduction study is often performed in conjunction with an upper extremity evaluation to assess conduction velocity and latency. Normative values have been described. In cases of unilateral paralysis, the normally functioning side is often used as the baseline for comparison [40]. Diaphragm electromyography is included in a comprehensive evaluation to assess motor amplitude deficits and assists in stratifying those

patients that may be candidates for phrenic nerve reconstruction. The technical difficulty of this assessment supersedes that of most other electrodiagnostic testing due to the muscle not being readily accessible transcutaneously and the inherent risk of pneumothorax.

## Neuromuscular Pathology

The pathological processes responsible for diaphragmatic paralysis typically involve one or more sites of insult to the neuromuscular pathway. This pathway originates in the brain and cervical spine, emerges through the cervical roots 3–5, extends down the phrenic nerve, and terminates beyond the neuromuscular junction in the diaphragm itself. Aside from the central nervous system disorders previously described, e.g., stroke, spinal cord injury, and ALS, direct injury to the cervical roots and/or phrenic nerve may occur in any number of ways.

Peripheral nerve injury can result from complete transection or alternatively can be the consequence of traction, (hypo-)thermal, compression, or pharmacological injury. Regardless of the manner in which the injury is sustained, in all non-transection processes, the end result is usually segmental nerve anoxia leading to demyelination and, ultimately, axonal loss. This description follows the nerve injury classification system of Seddon and Sunderland that has gained universal acceptance and forms the basis for current surgical treatment algorithms [41].

---

## Treatment Options for Diaphragmatic Paralysis

### Positive Airway Pressure Supplementation (CPAP/BiPAP)

Continuous positive airway pressure (CPAP) and bi-level positive airway pressure (BiPAP) are two treatment modalities for respiratory sleep disorders that effectively maintain airway patency and reduce or prevent apneic events. The reduction in inspiratory muscle force that occurs with diaphragmatic

paralysis commonly leads to sleep abnormalities detectable on polysomnography. Positive airway pressure supplementation using either CPAP or BiPAP is a recommended treatment, although the ability to maintain higher pressures during inspiration and then provide a lower level during the expiratory phase would seem to favor BiPAP for an inspiratory muscle disorder. This may distinguish sleep disorders due to isolated diaphragmatic paralysis from obstructive sleep apnea patients with upper airway obstruction that could benefit from higher pressures during both phases of breathing. Khan et al. (2014) retrospectively reviewed 66 patients with unilateral or bilateral diaphragmatic paralysis, all of whom exhibited abnormal sleep studies consistent with sleep-disordered breathing [42]. Patients exhibited demonstrable improvements using positive airway pressure supplementation. Unsurprisingly, less than 40% tolerated CPAP with the rest requiring BiPAP.

### Plication of the Diaphragm

This section will focus on mechanics, method, timing, and results of diaphragmatic plication. The surgical restructuring of the diaphragm attempts to expand the thoracic volume and eliminate paradoxical motion in order to improve ventilation mechanics and pulmonary function and decrease symptomatic dyspnea. Diaphragmatic plication is indicated when symptomatic dyspnea occurs secondary to permanent phrenic nerve paralysis, and other methods of reinnervation or pacing are not available. Contraindications are relative and depend on the severity of the comorbidity and the significance of the dyspnea.

The vital role of the diaphragm in respiration is obvious, though its contribution varies based on position and sleep. The diaphragm is responsible for 56% of the tidal volume in the awake, supine patient and up to 81% during periods of deep sleep [43]. The aim of plication is to minimize the loss of thoracic space and prevent paradoxical motion. Plication decreases atelectasis of the involved lung and improves ventilation perfusion mismatch [44, 45]. Wright et al. demonstrated this diaphragmatic correction results in a signifi-

cant increase in total lung capacity, vital capacity, expiratory reserve volume, functional residual capacity, and arterial PaO<sub>2</sub>. Diaphragm plication has also been found to improve spirometry results when testing is performed in both sitting and supine positions [46].

The traditional approach is through standard posterolateral thoracotomy [46–49]. With the advent of modern, minimally invasive surgery, a video-assisted thoracic surgical (VATS) approach has slowly replaced open thoracotomies [49, 50]. Gazala and colleagues examined 126 studies on diaphragmatic paralysis, reviewing 13 representing the best evidence of repair, and compared VATS approach with thoracotomy. They found that a VATS approach achieves similar results based on pulmonary function tests (PFTs), dyspnea scores and functional assessment with shorter length of stay, lower complications rates, and mortality rate [51]. Several authors have supported a laparoscopic approach [52–54]. Both VATS and laparoscopic approaches are minimally invasive and offer unique benefits. There is no clear benefit of either, and the approach should be dictated by the surgeon's preference and experience [54]. The technique involves a suture line running parallel to the thoracotomy that is repeated until appropriate tension is created [46, 47]. Others have described a series of horizontal mattress sutures with or without pledgets in varying directions [44, 50, 52, 54].

The timing of the repair is based on the likely mechanism of injury. Cold ice slurry cardioplegia is probably the most thoroughly studied etiology of phrenic nerve injury. Several studies have demonstrated that cold injury to the phrenic occurs in 52–69% of patients, though it may resolve up to 2 years after the initial insult [14, 38, 48, 55, 56]. Although no conclusive studies exist on the perfect timing of repair in permanent injury, a 6-month waiting period typically allows for sufficient recovery from the time of injury in order to determine permanent damage. Plication should be reserved for those patients with documented diaphragmatic paralysis and a significant dyspnea score. Morbidly obese patients and those with long-standing paralysis seem to be less likely to benefit from this repair [49]. Although



only one of four vent-dependent patients was weaned from the ventilator after plication, 17 of 19 patients who were unable to work secondary to dyspnea were able to return to work by 6 months following plication [44].

---

## Phrenic Nerve Reconstruction

### Background

Scattered case reports in the 1980s and 1990s have described typically the acute repair of the phrenic nerve following trauma or after tumor resection [57, 58]. Until recently, it was not widely accepted to pursue delayed nerve repair in patients with unilateral or bilateral diaphragmatic paralysis. While brachial plexus injuries have been treated for decades in an acute or delayed manner using well-established nerve reconstruction methods, there has not been the same focus for phrenic nerve injuries, leaving diaphragm plication as the only interventional therapy. In 2011, the primary author published the first small series on successful phrenic nerve reconstruction, demonstrating partial or complete diaphragmatic recovery in 89% of the treatment group [24].

### Surgical Treatment

The successful surgical treatment of phrenic nerve injuries occurs in a clinical scenario of a segmental nerve injury in the neck, mediastinum, and/or chest cavity. These injuries are amenable to a combination of nerve decompression and interposition grafting or neurotization. For example, patients with phrenic nerve injury occurring from interscalene nerve blocks performed during rotator cuff surgery are often found intraoperatively to have dense fibrous and vascular adhesions in the region of the C5 root contribution to the phrenic nerve and proximal phrenic nerve proper. Appropriate therapy consists of meticulous nerve decompression and interpositional grafting to “bypass” the site of lesion. Both techniques are believed crucial to maximizing success since it is not possible to confirm during

surgery whether decompression has sufficiently reversed the pathological process.

We have described pathological findings from various causative etiologies of phrenic nerve injury, including “Red Cross syndrome.” In this syndrome, the phrenic nerve is subject to compression neuropathy from an adherent and torturous transverse cervical artery and/or vein, likely the result of a post-inflammatory process (Table 10.1) [59]. Similar to other peripheral nerve surgical procedures, a successful outcome is based upon various factors, most notably superb technical methods and intensive rehabilitation to strengthen the atrophic muscle once reinnervation has been confirmed. Accordingly, the recovery process can be prolonged, often requiring 2–3 years for optimal recovery.


### Outcomes

Comparing results of phrenic nerve reconstruction to both historical cohorts from a meta-analysis of diaphragm plication outcomes, and a control group of nonsurgical observation, we have demonstrated at least a functional equivalency to plication at 1-year follow-up and results that are far superior to no treatment [3]. Furthermore, electrodiagnostic recovery, including both a 69% improvement in conduction latency and a motor amplitude increase of 37%, was significant in the phrenic nerve surgery group. This improvement did not occur with plication surgery or the nonsurgical group. Based upon the likelihood of slow, progressive improvement expected with aggressive rehabilitation protocols, we believe that successful outcomes of phrenic nerve surgery would likely supersede those of plication with longer follow-up.

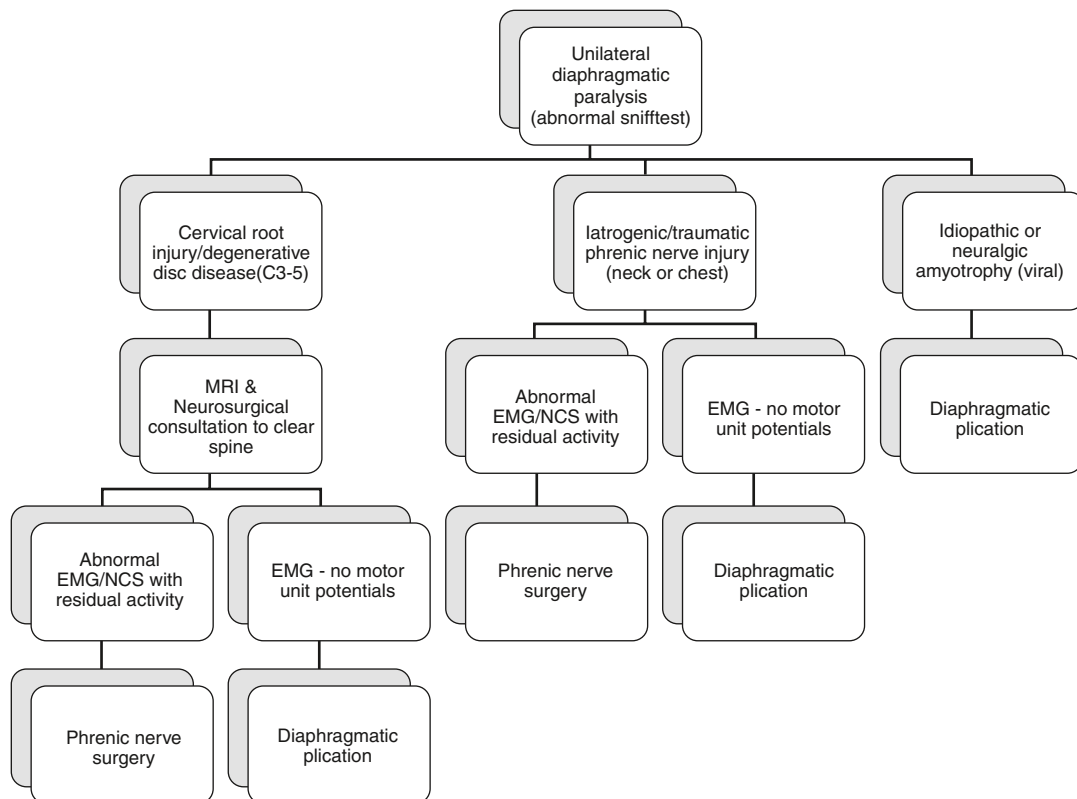
### Treatment Algorithm

In developing successful nerve reconstruction methods to restore function to a paralyzed diaphragm, it is now possible to create a comprehensive treatment algorithm for this condition that includes both phrenic nerve surgery and diaphragm plication for cases of unilateral

paralysis. An important concept in this algorithmic approach is that failure to reinnervate the paralyzed diaphragm after phrenic nerve surgery does not preclude a subsequent attempt at plication, whereas the failed plication would not be favorable for nerve surgery due to the likelihood of dense scarring in the muscle itself. Therefore, if electrodiagnostic testing reveals intact voluntary motor units, phrenic nerve surgery should be offered as the first-line treatment. Alternatively, if progressive deterioration in the muscle is evident on electromyography or the patient is a poor candidate (i.e., elderly, diabetic neuropathy, immunosuppressed), the likelihood of reinnervation is vastly reduced, and the patient is better served with a plication procedure (Figs. 10.4 and 10.5).



**Fig. 10.4** Intraoperative example of “Red Cross syndrome,” a vascular compression of the phrenic nerve (looped proximal and distal to the crossing blood vessel) caused by the transverse cervical artery



**Fig. 10.5** Published algorithmic approach to the treatment of diaphragmatic paralysis based upon results of electrodiagnostic evaluation (Reprinted with permission, Kaufman et al. CHEST)

## Ventilator Dependency

### Demographics

Spinal cord injury in the cervical region leads to complete or incomplete tetraplegia, with a 38% incidence of ventilator dependency at the time of hospital discharge [60]. Based on an estimated 12,500 new spinal cord injuries annually in the United States, roughly 60% of which are partial or complete tetraplegia, there are approximately 1600 new cases per year of ventilator dependency associated with this debilitating condition. The premature morbidity and mortality associated with ventilator dependency in these patients have been clearly documented as well as the increased healthcare costs accrued despite a reduction in longevity.

Amyotrophic lateral sclerosis (ALS) is another neurological disorder leading almost universally to ventilator dependency. There are an estimated 5600 new cases of ALS annually in the United States or an incidence of 2 per 100,000 per year [61]. Similar to spinal cord injury statistics, the impact of ventilator dependency is profound, with respiratory causes of mortality as the primary source of early mortality in this disease. There are several other central nervous system disorders frequently leading to partial or complete ventilator dependency, including central hypoventilation syndrome, stroke, Pompeii's disease, and brainstem tumors.

### Consequences of Positive Pressure Ventilation on the Diaphragm

A landmark study by Levine et al. (2008) clearly demonstrated rapid disuse atrophy occurring in the diaphragm muscles of patients requiring positive pressure ventilation [62]. After only 18 h of mechanical ventilation, there was a 57% decrease in the more functional type I slow-twitch fibers compared to controls. Oxidative stress and proteolysis were seen even with limited periods of inactivity. Although it is unclear whether the early and rapid deterioration is reversible, the implications are likely profound

pertaining to the impact on the diaphragm in patients requiring anything more than a few days of mechanical ventilation.

In ventilator-dependent cervical tetraplegics, it is necessary to evaluate carefully the effectiveness of noninvasive weaning methods and consider the negative consequence of prolonging inevitable weaning failure. Although, in many cases, the implementation of well-established weaning methods leads to independent respiratory activity over a period of weeks to months following injury, it must be remembered that interventional treatment options, such as diaphragm pacemakers, require an intact phrenic nerve and at least some functional muscle to be effective. Long-term ventilator dependency undoubtedly leads to the transgression of a threshold beyond which there is profound irreversible diaphragmatic atrophy. Especially in patients who have cervical spinal cord injury and concomitant phrenic nerve degeneration, that timeframe is likely to be 18–24 months, after which time there may be complete loss of the motor end plates and a dramatic reduction in the success of any surgical intervention [63].

### Treatment Options

Diaphragm pacemakers can be extremely effective at partially or completely reversing ventilator dependency in high cervical tetraplegia [64]. The history of diaphragm pacing and an explanation of the technique will be detailed in another chapter. However, it is critical to also focus on those patients that are deemed unsuitable for this therapeutic option. As mentioned previously, when there is loss of phrenic nerve integrity, diaphragm pacemakers will be ineffective. These unfortunate patients are often told there is no chance at ventilator weaning, and they must accept a life on mechanical ventilation with the associated morbidity and early mortality.

In 2000, Krieger and Krieger published the first report of simultaneous nerve transfers and pacemaker implantation to overcome ventilator dependency in patients with combined spinal cord injury and phrenic nerve degeneration [2].

The rationale for the dual approach was to first restore phrenic nerve integrity by transferring an intact nerve source that could subsequently permit pacemaker activation of the diaphragm. More recently, the primary author (M.R.K.) demonstrated a 93% reinnervation rate in 14 patients undergoing nerve transfers and pacemaker implantation [65]. Partial or complete ventilator weaning was achieved in 62%, and it was believed that due to an average interval of 34 months between injury and treatment, many patients had suffered significant and irreversible diaphragm atrophy preventing clinical success.

Increasingly, rehabilitation efforts for spinal cord injury patients have focused on functional electrical stimulation of peripheral nerves to prevent irreversible muscle atrophy [66]. Although this has been applied primarily for the upper and lower extremities, conceptually this could also prevent diaphragmatic atrophy in patients that may eventually be weaned or in more severe injuries when noninvasive methods are more likely to be unsuccessful, thus necessitating surgical intervention. The application of electrical stimulation in this latter setting would most certainly increase the likelihood of achieving independent respiratory activity with or without a pacemaker. Unfortunately, the technical difficulty of placing transcutaneous electrodes near the phrenic nerve or nerve-muscle interface makes noninvasive stimulation therapy more challenging than it is for the extremities.

In spinal cord injury patients who have suffered irreversible and severe diaphragmatic atrophy, it is possible to consider the most sophisticated reconstructive techniques for restoring the neuromuscular components of the respiratory system. In addition to the use of nerve reconstruction and implantation of a diaphragm pacemaker, an atrophic diaphragm may be “replaced” or “enhanced” by transferring an intact muscle with its own neurovascular connection. This application would not be unique to the respiratory system but is considered standard practice for the most severe injuries in the facial muscles and extremities [67]. Replacing or restoring diaphragm neuromuscular activity has also been reported in young children with

congenital diaphragmatic hernia [68]. As of this writing, we have begun clinical application of this comprehensive procedure and have demonstrated immediate, intraoperative activity of the neo-diaphragm using an implanted pacemaker.

## References

1. Nogajski J, Engel S, Kierman M. Focal and generalized peripheral nerve dysfunction in spinal cord-injured patients. *J Clin Neurophysiol.* 2006;23:273–9.
2. Krieger LM, Krieger AJ. The intercostal to phrenic nerve transfer: an effective means of reanimating the diaphragm in patients with high cervical spine injury. *Plast Reconstr Surg.* 2000;105:1255–61.
3. Kaufman MR, Elkwood AI, et al. Functional restoration of diaphragmatic paralysis: an evaluation of phrenic nerve reconstruction. *Ann Thorac Surg.* 2014;97:260–6.
4. Fuller DD, Sandhu MS, Doperalski NJ, et al. Graded unilateral cervical spinal cord injury and respiratory motor recovery. *Respir Physiol Neurobiol.* 2009;165:245–53.
5. Golder FJ, Fuller DD, Davenport PW, et al. Respiratory motor recovery after unilateral spinal cord injury: eliminating crossed phrenic activity decreases tidal volume and increases contralateral respiratory motor output. *J Neurosci.* 2003;23:2492–501.
6. Vinit S, Gauthier P, Stamegna JC, Kastner A. High cervical lateral spinal cord injury results in long-term ipsilateral hemidiaphragm paralysis. *J Neurotrauma.* 2006;23:1137–46.
7. Loukas M, Kinsella Jr CR, Louis Jr RG, et al. Surgical anatomy of the accessory phrenic nerve. *Ann Thorac Surg.* 2006;82:1870–5.
8. Hodges PW, SC Gandevia. Activation of the human diaphragm during a repetitive postural task. *J Physiol.* 2000;522 Pt 1:165–175.
9. Mizuno M, Secher NH. Histochemical characteristics of human expiratory and inspiratory intercostal muscles. *J Appl Physiol.* 1985;67:592–8.
10. McKenzie DK, Gandevia SC, Shorey CD. A histochemical study of human inspiratory muscles. *Proc Int In Physiolol.* 1983;40:351–4.
11. Bruin P, Ueki J, Bush A, et al. Diaphragm thickness and inspiratory strength in patients with Duchenne muscular dystrophy. *Thorax.* 1997;52:472–5.
12. Mehta Y, Vats M, Singh A, et al. Incidence and management of diaphragmatic palsy in patients after cardiac surgery. *Indian J Crit Care Med.* 2008;12:91–5.
13. Efthimiou J, Butler J, Woodham C, et al. Diaphragm paralysis following cardiac surgery: role of phrenic nerve cold injury. *Ann Thorac Surg.* 1991;52:1005–8.
14. Devita M, Robinson LR, Rehder J, et al. Incidence and natural history of phrenic neuropathy occurring during open heart surgery. *Chest.* 1993;103:850–6.

15. Mak P, Irwin M, Ooi C, et al. Incidence of diaphragmatic paralysis following supraclavicular brachial plexus block and its effect on pulmonary function. *Anaesthesia*. 2001;56:352–6.
16. Guirguis M, Karroum R, Abd-Elsayed AA, Mounir-Soliman L. Acute respiratory distress following ultrasound-guided supraclavicular block. *Ochsner J*. 2012;12:159–62.
17. Saint Raymond C, Borel JC, Wuyam B, et al. Persistent phrenic palsy following interscalene block, leading to chronic respiratory insufficiency and requiring long-term non-invasive ventilation. *Respir Med*. 2008;1:253–5.
18. Robaux S, Bouaziz H, Boisseau N. Persistent phrenic nerve paralysis following interscalene brachial plexus block. *Anesthesiology*. 2001;95:1519–21.
19. Tolge C, Iyer V, McConnell J. Phrenic nerve palsy accompanying chiropractic manipulation of the neck. *South Med J*. 1993;86:688–90.
20. Schram DJ, Vosik W, Cantral D. Diaphragmatic paralysis following cervical chiropractic manipulation: case report and review. *Chest*. 2001;119:638–40.
21. Coleman J. Complications in head and neck surgery. *Surg Clin N Amer*. 1986;66:149–67.
22. Bulkley GB, Bass KN, Sepsenson GR, et al. Extended cervicomedial thymectomy in the integrated management of myasthenia gravis. *Ann Surg*. 1997;226:324–34.
23. Salati M, Cardillo G, Carbone L, et al. Iatrogenic phrenic nerve injury during thymectomy: the extent of the problem. *J Thorac Cardiovasc Surg*. 2010;139:e77–8.
24. Kaufman M, Elkwood A, Rose M, et al. Reinnervation of the paralyzed diaphragm: application of nerve surgery techniques following unilateral phrenic nerve injury. *Chest*. 2011;140:191–7.
25. Willaert W, Kessler R, Deneffe G. Surgical options for complete resectable lung cancer invading the phrenic nerve. *Acta Chir Belj*. 2004;104:451–3.
26. Sano Y, Oto T, Toyooka S, et al. Phrenic nerve paralysis following lung transplantation. *Kyobu Geka*. 2007;60:993–7.
27. Coene LN. Mechanisms of brachial plexus lesions. *Clin Neurol Neurosurg*. 1993;95(Suppl):S24–9.
28. Burnett M, Zager E. Pathophysiology of peripheral nerve injury: a brief review. *Neurosurg Focus*. 2004;16:E1.
29. Upton AR, McComas AJ. The double crush in nerve entrapment syndromes. *Lancet*. 1973;2:359–62.
30. Richardson JK, Forman GM, Riley B. An electrophysiological exploration of the double crush hypothesis. *Muscle Nerve*. 1999;22:71–7.
31. Valls-Sole J, Solans M. Idiopathic bilateral diaphragmatic paralysis. *Muscle Nerve*. 2002;25:619–23.
32. Marvisi M, Balzarini L, Mancini C, et al. A rare case of dyspnoea the parsonage-turner syndrome. *J Med Cases*. 2012;3:169–71.
33. Como J, Sutton E, McCunn M, et al. Characterizing the need for mechanical ventilation following cervical spinal cord injury with neurologic deficit. *J Trauma*. 2005;59:912–6.
34. Shoesmith C, Findlater K, Rowe A, et al. Prognosis of amyotrophic lateral sclerosis with respiratory onset. *J Neurol Neurosurg Psychiatry*. 2006;78:629–31.
35. Moris G, Arias M, Terrero J, et al. Ipsilateral reversible diaphragmatic paralysis after pons stroke. *J Neurol*. 2011;259:966–8.
36. Parke WW, Whalen JL. Phrenic paresis—a possible additional spinal cord dysfunction induced by neck manipulation in cervical spondylotic myelopathy (CSM): a report of two cases with anatomical and clinical considerations. *Clin Anat*. 2001;14:173–8.
37. Steier J, Jollet CJ, Seymour J, et al. Sleep-disordered breathing in unilateral diaphragm paralysis or severe weakness. *Eur Respir J*. 2008;32:1479–87.
38. Summerhill EM, El-Sameed YA, Glidden TJ, et al. Monitoring recovery from diaphragm paralysis with ultrasound. *Chest*. 2008;133:737–43.
39. Karaoğlu P, Yiş U, Öztura I, et al. Phrenic nerve palsy associated with brachial plexus avulsion in a pediatric patient with multitrauma. *Pediatr Emerg Care*. 2013;28:922–3.
40. Chen R, Collins S, Remtulla H, et al. Phrenic nerve conduction study in normal subjects. *Muscle Nerve*. 1995;18:330–5.
41. Sunderland S. Nerves and nerve injuries. 2nd ed. New York: Churchill Livingstone; 1978.
42. Khan A, Morgenthaler T, Ramar K. Sleep disordered breathing in isolated unilateral and bilateral diaphragmatic dysfunction. *J Clin Sleep Med*. 2014;10:509–15.
43. Tusiewicz K, Moldofsky H, Bryan AC, et al. Mechanics of the rib cage and diaphragm during sleep. *J Appl Physiol Respirat Environ Exerc Physiol*. 1977;43:600–2.
44. Freeman R, Wozniak T, Fitzgerald E. Functional and physiologic results of video-assisted thoracoscopic diaphragm plication in adult patients with unilateral diaphragm paralysis. *Ann Thorac Surg*. 2006;81:1853–7.
45. Tsakiridis K, Visouli A, Zarogoulidis P, et al. Early hemi-diaphragmatic plication through a video assisted minithoracotomy in post cardiomy phrenic nerve paresis. *J Thorac Dis*. 2012;4:56–68.
46. Wright D, Williams J, Ogilvie C, et al. Results of diaphragmatic plication for unilateral diaphragmatic paralysis. *J Thorac Cardiovasc Surg*. 1985;90:195–8.
47. Graham D, Kaplan D, Hind CR, et al. Diaphragmatic plication for unilateral diaphragmatic paralysis: a 10-year experience. *Ann Thorac Surg*. 1990;49:248–52.
48. van Onna I, Metz R, Jekel L, et al. Post cardiac surgery phrenic nerve palsy: value of plication and potential for recovery. *Euro J Card Thorac Surg*. 1998;14:179–84.
49. Freeman R, Van Woerkom J, Vyverberg A, et al. Long term follow-up of the functional and physiologic results of diaphragm plication in adults with unilateral diaphragm paralysis. *Ann Thorac Surg*. 2009;88:1112–7.
50. Gharagozloo F, McReynolds SD, Snyder L. Thoracoscopic plication of the diaphragm. *Surg Endosc*. 1995;9:1204–6.

51. Gazalaa S, Hunt I, Bédard E. Diaphragmatic plication offers functional improvement in dyspnea and better pulmonary function with low morbidity. *Interact Cardio Vasc Thorac Surg.* 2012;15:505–8.
52. Huttel TP, Wichmann MW, Reichart B, et al. Laparoscopic diaphragmatic plication. Long-term results of a novel surgical technique for postoperative phrenic nerve palsy. *Surg Endosc.* 2004;18:547–51.
53. Hu J, Wu Y, Wang J, et al. Thoracoscopic and laparoscopic plication of the hemidiaphragm is effective in the management of diaphragmatic eventration. *Pediatr Surg Int.* 2014;30:19–24.
54. Groth SS, Rueth NM, Kast T, et al. Laparoscopic diaphragmatic plication for diaphragmatic paralysis and eventration: an objective evaluation of short-term and midterm results. *J Thorac Cardiovasc Surg.* 2010;139:1452–6.
55. Cohen A, Katz M, Katz R, et al. Phrenic nerve injury after coronary artery grafting- is it always benign? *Ann Thorac Surg.* 1997;64:148–53.
56. Gayan-Ramirez G, Gosselin N, Troosters T, et al. Functional recovery of diaphragm paralysis: a long term follow up study. *Respir Med.* 2008;102:690–8.
57. Brouillette RT, Hahn YS, Noah ZL, et al. Successful reinnervation of the diaphragm after phrenic nerve transection. *J Pediatr Surg.* 1986;21:63–5.
58. Schoeller T, Ohlbauer M, Wechselberger G, et al. Successful immediate phrenic nerve reconstruction during mediastinal tumor resection. *J Thorac Cardiovasc Surg.* 2001;122:1235–7.
59. Kaufman M, Willekes L, Elkwood A, et al. Diaphragm paralysis caused by transverse cervical artery compression of the phrenic nerve: the Red Cross syndrome. *Clin Neurol Neurosurg.* 2012;114:502–5.
60. Kornblith LZ, Kutcher ME, Ra C, et al. Mechanical ventilation weaning and extubation after spinal cord injury: a western trauma association multicenter study. *J Trauma Acute Care Surg.* 2013;75(6):1060–9.
61. The ALS Association. <http://www.alsa.org/about-als/facts-you-should-know.html>. 2015. Accessed 2 Sept 2015.
62. Levine S, Nguyen T, Taylor N, et al. Rapid disuse atrophy of diaphragm fibers in mechanically ventilated humans. *N Engl J Med.* 2008;358:1327–35.
63. Wiertz-Hoessels EL, Krediet P. Degeneration of the motor End-plates after neurectomy in the Rat and the rabbit. *Acta Morphol Neerl Scand.* 1965;6:179–93.
64. Tedde M, Vasconcelos F, Hajjar L, et al. Diaphragmatic pacing stimulation in spinal cord injury: anesthetic and perioperative management. *Clinics.* 2012;67:1265–9.
65. Kaufman M, Elkwood A, Aboharb F, et al. Diaphragmatic reinnervation in ventilator-dependent patients with cervical spinal cord injury and concomitant phrenic nerve lesions using simultaneous nerve transfers and implantable neurostimulators. *J Reconstr Microsurg.* 2015;31:391–5.
66. Leem M, Kiernan M, Macefield V, et al. Short-term peripheral nerve stimulation ameliorates axonal dysfunction after spinal cord injury. *J Neurophysiol.* 2015;113:3209–18.
67. Magden O, Tayfur V, Edizer M, et al. Anatomy of gracilis muscle flap. *J Craniofac Surg.* 2010;21:1948–5.
68. Horta R, Henriques-Coelho T, Costa J, et al. Fascicular phrenic nerve neurotization for restoring physiological motion in a congenital diaphragmatic hernia reconstruction with a reverse innervated latissimus dorsi muscle flap. *Ann Plast Surg.* 2015;75:193–6.